

OraGEN® Cellular Bone Matrix

Case performed by: Dr. Edgard El Chaar, New York, NY

CASE STUDY

Patient & Diagnosis:

- A 65-year-old male, missing second premolar and with one first molar that is supporting a three-unit bridge. Recurrent cavities were detected that required removal of restoration. The site in question has less than 1mm in crestal bone available.

Previous Treatment:

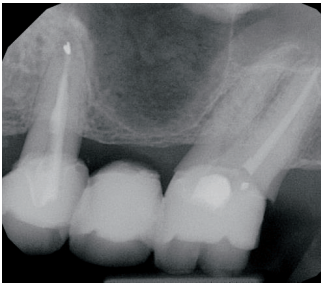
- None other than the extraction and making the three unit bridge.

Intervention:

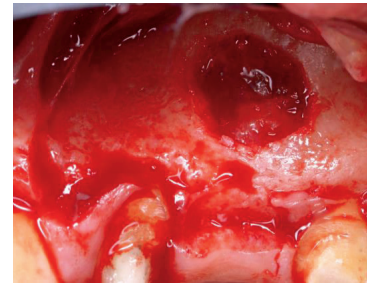
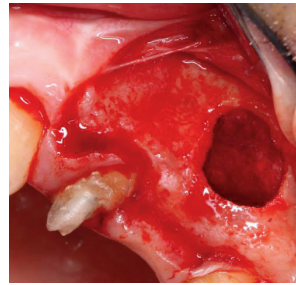
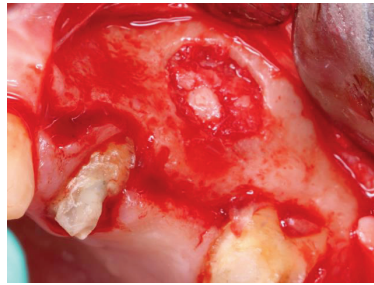
- A lateral sinus elevation using OraGen 100% placed.

Outcome:

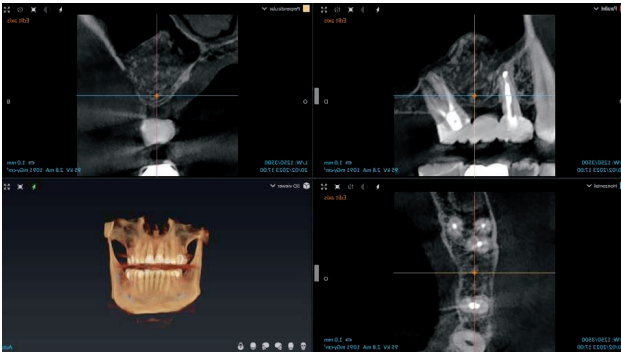
- An adequate amount of bone regeneration occurred for the placement of an implant in the position of the second premolar. The patient was able to be successfully restored with three individual crowns despite having <1mm of crestal bone prior to treatment.



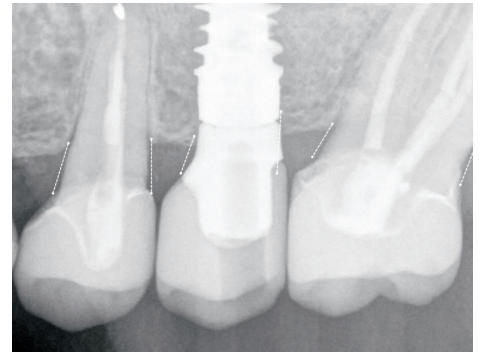
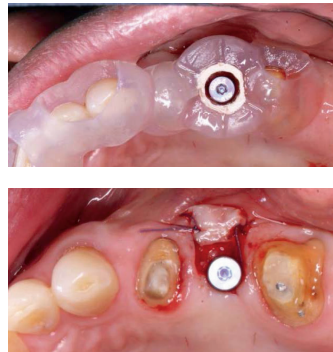
As we see in the radiograph the lack of the crestal bone



In these three clinical views, we can appreciate the lateral window and the placement of 100% OraGen



Immediately post grafting



One year post implant placement

SALVIN®

Everything For Your Implant Practice But The Implants®

800-535-6566 • www.salvin.com

© 2025 Salvin Dental Specialties, LLC All Rights Reserved. REV. 05-2025